

## Original article

# Minimal access surgery in hydatid cyst liver

<sup>1</sup>Dr. Devika Rakesh , <sup>2</sup>Dr. B.S Pathania

<sup>1</sup>Post graduate Resident, Department of Surgery, ASCOMS & Hospital

<sup>2</sup>Professor, Department of Surgery ASCOMS & Hospital

Corresponding author- Dr.Devika Rakesh

### ABSTRACT:

**Background:** Hydatid disease is a parasitic infection of the liver and other organs in the body and Conservative surgical management by conventional laparotomy is the main stay of treatment.Minimal access surgery in this disease has shown equally good results in few studies and experience is limited. Therefore, it was proposed to study clinical outcome in patients suffering from hydatid cyst liver following minimal access surgery.

**Methods:** In this case series ,30 Patients suffering from hydatid cyst liver were subjected to minimal access surgery over a period of 2 years using Palanivelu Hydatid System (PHS) cannula and were followed up post operatively.

**Results:** Most common clinical presentation was Abdominal lump. Residual cavity was managed by omentoplasty and drainage in 21 cases (70%), omentoplasty alone in 3 cases (10 %) and drainage alone in 6 cases (20%) with no conversion to open procedure.2 patients had post-operative biliary leakage managed by ERCP and stenting. There was port site infection in 1 case managed conservatively. A mean follow-up of 13 months showed no recurrence, no port site hernia and patient had a better quality of life.

**Conclusions:** Minimal access surgery in the treatment of hydatid cyst has brought revolutionized change in the post-operative morbidity with advantages of less pain, rapid recovery, good cosmetic results, no spillage and less recurrence without compromising the basic rules of treating the hydatid cyst liver. We strongly recommend minimal access surgery as a superior and viable alternative in the treatment of hydatid cyst in the accessible segments of liver

**Keywords:** minimal access hepatic hydatid cyst,PHS cannula

### BACKGROUND

Hydatid disease, also known as echinococcosis, is a parasitic infection of the liver and other organs by the flatworm echinococcus (cestode).It is an endemic parasitic disease in Mediterranean countries, North Africa, Turkey, the Middle East, Australia, New Zealand, South America, Baltic areas, the Philippines, Northern China, and the Indian subcontinent.However, physicians can encounter this disease anywhere in the world sporadically. Man is a secondary host and becomes infected by ingesting vegetables fouled by dogs or more directly by handling the parasite -infested dogs as pets which are the definitive host. The most common domestic cycle can also occur in cattle, swine, goats, horse, camels and human. Hydatid liver disease afflicts all age groups in both sexes with equal frequency. Hydatid liver cysts expand slowly and asymptotically and thus tend to be quite large at presentation. If left untreated, the cyst grows & follows one of several courses: forms fistulas into adjacent organs or the biliary system, ruptures into the peritoneal cavity causing seeding of multiple daughter cyst throughout the peritoneal cavity, developing daughter cyst with or rarely dying de novo. Older cysts have an increased risk of exogenous

daughter cyst formation, which is an important factor for recurrences of disease after surgery<sup>[1]</sup>. The most common site of occurrence of hydatid cysts in humans is the liver 50 -93 %<sup>[2]</sup>. The diagnosis of hydatid cyst is based on the several serological tests & radiological findings. Ultrasonography & CT scan are the best imaging modalities for the hydatid cyst. Ultrasonography detects 90% of hydatid liver cysts & is cost effective. However, CT is better than ultrasonography in localizing the cyst & delineating the extend of cyst.

For the sterilization of the cyst, various agents have been used over the time. Povidone (polyvinyl pyrrolidine) iodine, a potent scolical agent, has been proved more effective than hypertonic saline in preventing experimental peritoneal infection by *Echinococcus granulosus*<sup>[3]</sup>.

Conservative surgical management is the main stay of treatment for the majority of patients and radical procedures like total cysto-peri cystectomy, lobectomy or hepatectomy are reserved only for rare situations. Conservative surgical procedures being the mainstay of treatment have been so performed by conventional laparotomy, however with the advent of minimal access surgery, such procedures can be performed with this method<sup>[3]</sup>. Though the procedure can be performed laparoscopically with equally good results<sup>[4]</sup>, only few studies are available and experience is limited. Therefore, it was proposed to study clinical outcome in patients suffering from hydatid cyst liver following minimal access surgery.

#### AIMS AND OBJECTIVES

To study feasibility, safety and clinical outcome of minimal access surgery in patients suffering from hydatid cyst liver.

#### MATERIAL AND METHODS

30 Patients suffering from hydatid cyst liver were taken up for this study over a period of 2 years. Our exclusion criteria were patients with small hydatid cyst less than 5 cm diameter, posteriorly located cyst in the liver, cysts deep within the hepatic parenchyma, patients suffering from cirrhosis, bleeding diathesis and patients not fit for General anesthesia.

The patients were examined, investigated and hydatid cysts in these patients were classified on the basis of abdominal ultrasonography / Computerized tomography finding following Gharbi classification<sup>[5]</sup>.

STAGE-I : Univesicular hydatid cyst with liquid component only.

STAGE-II: Univesicular hydatid cyst with floating membranes.

STAGE-III: Multivesicular cyst with prominent liquid component.

STAGE-IV: Pseudo tumoral lesion with prominent solid component.

STAGE- V: Calcified solid lesion.

The patients were given Albendazole preoperatively in the dosage of 10mg/kg body weight/day in two divided doses for 14 days. Patients were informed about the procedure and its conversion to open as and when required for which written consent was taken.

In addition to the usual set of laparoscopic equipment and instruments, a special Palanivelu Hydatid System cannula (PHS) was used which consists of: a trocar, cannula and 5mm reducer.



FIGURE 1: PALANIVELU HYDATID SYSTEM CANNULA (PHS)

Principle of PHS for hydatid cyst: the cannula has 2 side channels one for CO<sub>2</sub> insufflation and another for suction. The suction side channel has an outer diameter of 12mm and inner diameter of 10mm. By connecting a powerful suction machine to this wide channel, a strong vacuum seal is created between the rim of cannula and the surface of hydatid cyst. This is essential in preventing spillage of hydatid fluid when the trocar is subsequently advanced into the hydatid cyst. The trocar can accommodate a 5mm of suction cannula, which is connected to another suction machine. Once the trocar has punctured the cyst, there are two suction forces working. This ensures rapid and complete evacuation of the hydatid fluid, hydatid sand and hydatid vesicle, if present. Operative technique: For hydatid cyst in the right lobe of the liver, the patient was positioned in left lateral position with a tilt of 45 degree and the operating surgeon stood on the left side of patient. For hydatid cyst in the left lobe of liver, the patient was placed in a modified lithotomy reverse trendelenburg position with the surgeon standing between legs of the patient. Pneumoperitoneum was created by using closed technique by Veress needle inserted in supraumbilical position. Port placement: for right hepatic cyst, the camera port was placed supraumbilically, One 10 mm Port for the right hand in the epigastrium and one 5mm port for the left hand in the right hypochondrium just below the liver edge. The 4<sup>th</sup> port was for a 12mm trocar cannula for hydatid cyst, which was placed in such a manner so that it came exactly over the hydatid cyst. For left hepatic cyst, camera port was placed supraumbilically, right hand working port (10 mm) in left hypochondrium while the left hand working port (5mm) in the epigastric region. The 12 mm port for trocar-cannula for hydatid cyst was placed exactly over the cyst. After introducing camera port through the umbilicus, hydatid cyst was identified and any adhesion present between the cyst and other structures was separated. After identifying the cyst, the hydatid trocar cannula was introduced into the abdominal cavity directly over the hydatid cyst, and then trocar was withdrawn once inside the peritoneal cavity, so that its tip was within the cannula, then it was advanced till its tip was in total contact with the hydatid cyst surface. Strong suction was applied through the side channel to create a strong negative pressure and maintain airtight contact between the rim of the cannula and cyst.

Thereafter, the trocar with 5mm suction nozzle on its side was connected to another suction machine introduced into the cannula and with steady pressure, was pushed into the cyst along with the cannula, so that any fluid spillage on the puncture of the cyst wall was immediately sucked out. A gauze piece soaked in 10% povidone iodine was wrapped around hydatid cyst cannula at its entry into cyst wall.

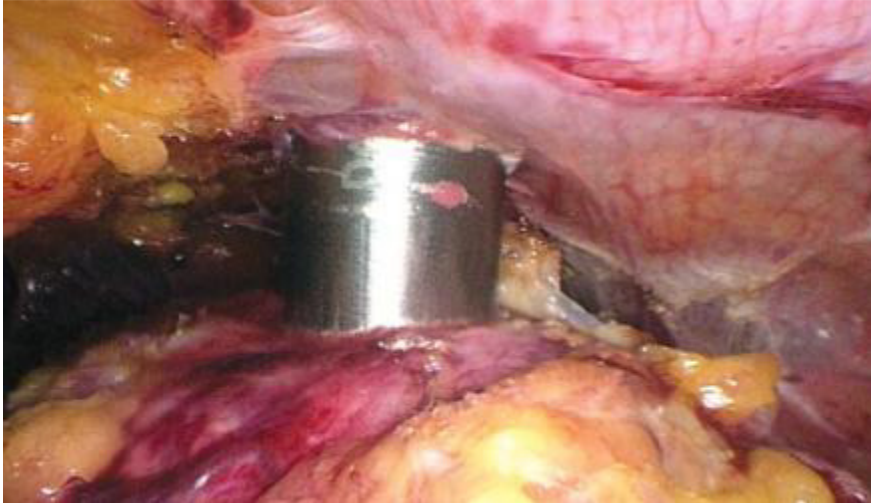

FIGURE 2: LAPAROSCOPIC VIEW OF EVACUATION OF CONTENTS FROM HYDATID CYST LIVER WITH PHS CANNULA

Once the hydatid cyst cannula was inside the hydatid cyst the trocar was removed and cavity was irrigated with povidone iodine 10% followed by normal saline through the main channel while maintaining continuous suction all the time simultaneously. The suction cannula, connected to separate suction machine, was introduced through right hand working port for sucking minimal leakage if at all occurred. Fragments of laminated membrane, daughter cyst, and debris were removed and were put in an endobag. Once, the returning normal saline was clear, telescope 5mm/10mm (30 degree) was introduced into the cavity through the cannula to visualize the interior of hydatid cyst cavity for the complete extraction of contents of the cavity & to look for any cysto-biliary communication.

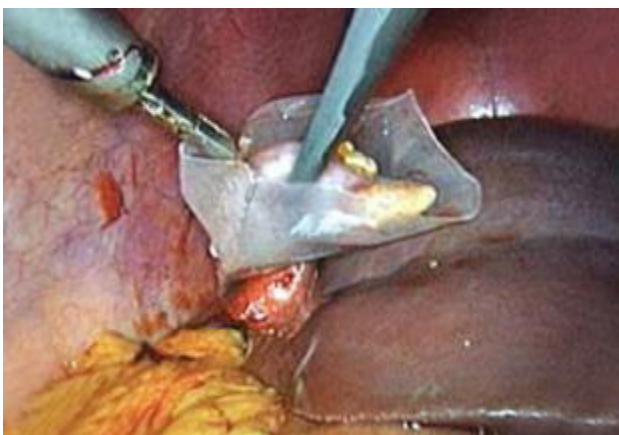


FIGURE 3:LAPAROSCOPIC VIEW OF PART OF THE HYDATID CYST WALL BEING REMOVED IN THE ENDOBAG AFTER UNROOFING

Management of cyst wall: After removing hydatid cyst cannula, the cyst wall was unroofed with the help of electric cautery hook and scissors, by going through the opening of cyst wall created by trocar cannula. Any redundant cyst wall was partially excised & thereby causing saucerization of the cavity. If any leftover fragment of laminated membrane was found, it was extracted out. Live omentum was taken into the cavity where it could be taken and was anchored to the cyst wall with the help of intracorporeal suture 2-0 polyglactin. In cases where, the size of the cavity was found large enough after omentoplasty, drain was kept in it. Another drain was kept in sub hepatic space (28/32 in size). Hemostasis was maintained. Port closure was done, drains fixed and antiseptic dressing done. One patient, who had recurrence of hydatid cyst liver previously operated by open procedure had incisional hernia too, so she was subjected to left mesh hernioplasty simultaneously.

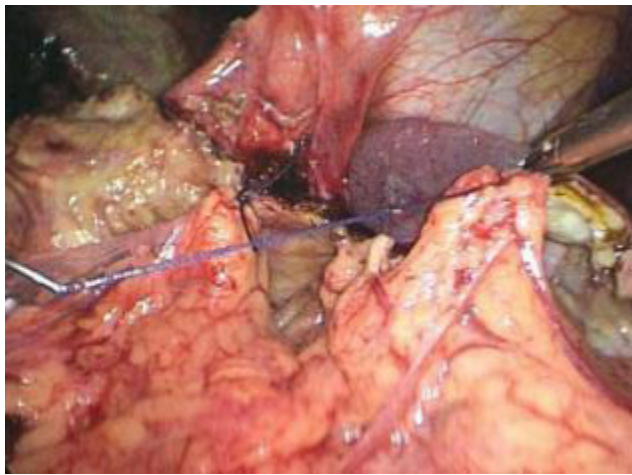


FIGURE 4 : LAPAROSCOPIC VIEW OF OMENTUM BEING PLACED INSIDE THE CYST CAVITY

Antibiotic, analgesics and albendazole 400 mg twice a day for 21 days, 3 cycles with gap of 21 days between the cycles were routinely prescribed to the patients during the postoperative period and they were followed up.

Statistical Analysis: was conducted with the help of SPSS software 21. Variables were presented as mean and standard deviation for quantitative and percentages for qualitative or as deemed appropriate.

#### RESULTS

In our study the age of the patients varied from 24 to 64 years with a mean age of  $38.16 \pm 8.9$  years. Out of 30 patients, 21 cases (70%) were males and 9 cases (30%) females. Majority of the patients i.e. 21 cases presented with abdominal swelling (70%), 6 patients (20%) presented with abdominal pain and 3 patients (10%) were detected accidentally. Symptoms like fever, anaphylaxis or nausea wasn't present in any patient. As seen on ultrasonography, right lobe of liver was involved in 23 cases (76.66%), left lobe in 4 cases (13.33%) and both lobes involved in 3 cases (10%).

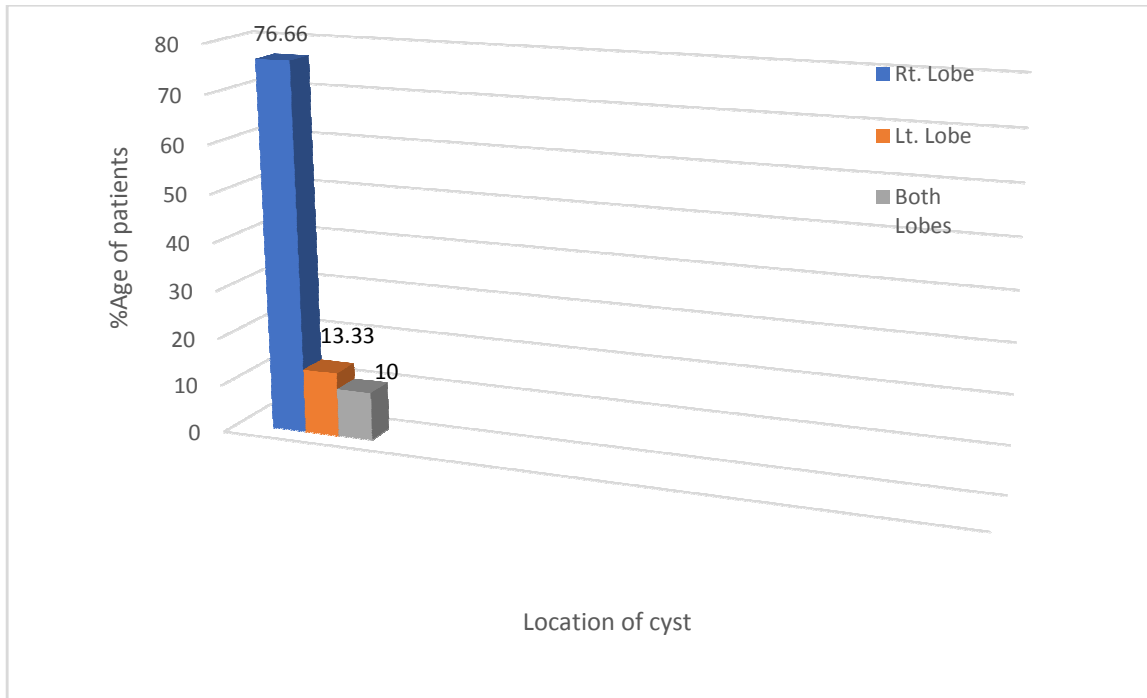


FIGURE 5: SHOWING DISTRIBUTION OF PATIENTS ACCORDING TO THE LOCATION OF HYDATID CYST LIVER (ON ULTRASONOGRAPHY)

The mean size of the cyst was  $9.61 \pm 2.47$  cm. (5.5-14.5cm). In our study the disease was staged according to the criteria of Gharbi. Most of the patients 50% were in stage III.

TABLE 1: SHOWING DISTRIBUTION OF PATIENTS ACCORDING TO THE STAGE OF DISEASE BY GHARBI GRAPH

n = 30 (no. of cases)

STAGE OF DISEASE	NO. OF PATIENTS	% AGE
STAGE I	9	30
STAGE II	6	20
STAGE III	15	50
STAGE IV	0	0
STAGE V	0	0

**MANAGEMENT OF CYST CAVITY:**

Residual cavity of cyst was managed by unroofing of the cyst wall and drainage alone in 6 patients (20%), omentoplasty alone in 3 patients (10%) or omentoplasty and drainage in 21 patients (70%).

**TABLE 2: SHOWING DISTRIBUTION OF PATIENTS ACCORDING TO THE MANAGEMENT OF CYST CAVITY**

n = 30 (no. of cases)

TYPE OF MANAGEMENT	NO. OF PATIENTS	% AGE
OMENTOPLASTY AND DRAINAGE	21	70
DRAINAGE ALONE	6	20
OMENTOPLASTY ALONE	3	10

There was no conversion to open procedure in our study and the mean operating time was  $82.4 \pm 13$  mins. There were no intraoperative complications related to general anesthesia, pneumoperitoneum, anaphylactic shock. However, there was one case of diaphragmatic injury while operating on a superior-laterally located right hepatic hydatid which was sutured with polypropylene. In another case, after managing the hydatid cyst, laparoscopic mesh hernioplasty was also done for the repair of incisional hernia present over the medial aspect of her previous scar. In the early post-operative period two patients developed biliary leakage both of whom were managed with ERCP and stenting following which the biliary fistula closed spontaneously in 4 weekstime and drain was removed. Port site infection was seen in one patient managed conservatively with antibiotics and dressings.

**TABLE No.3: SHOWING THE POST OPERATIVE COMPLICATIONS**

n =30 (no. of cases)

COMPLICATIONS	NO. OF PATIENTS	% AGE
PORT SITE INFECTION	1	3.33
BILIARY FISTULAS	2	6.66
ANAPHYLAXIS	-	
RECURRENCE	-	
TOTAL	3	10%

The drains were kept in Morrison’s pouch and cyst cavity. In most of the patients the drain was kept for a period of 5-10 days (mean- 7 days). In two patients with biliary fistula drain was kept for 4 weeks. In our study, the mean hospital stay was  $8.06 \pm 3.70$  days with a range of 5-20 days. 2 out of 20 patients had delayed discharge from the hospital because of biliary fistula.

Pain was assessed at 24 hours post-operatively using visual analogue scale (VAS). 27 patients (90%) had mild pain, 3 patients (10%) had moderate pain and none had severe pain. Post-operative follow-up was done using ultrasonography, which showed collapsed cyst cavity, no recurrences at surgical site or any other site, no pain, no port site hernia and patient had better quality of life. The mean follow up in our study was  $13.1 \pm 3.15$  months.

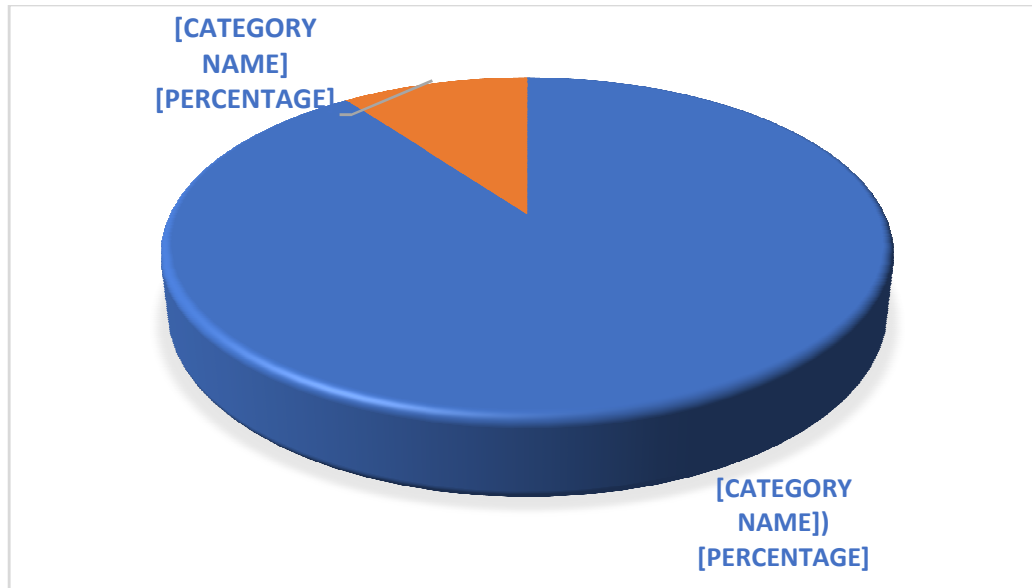


FIGURE 6: SHOWING DISTRIBUTION OF CASES ACCORDING TO POST OPERATIVE PAIN ASSESSMENT USING VISUAL ANALOGUE SCALE

#### DISCUSSION

Hydatid disease of liver needs treatment even in asymptomatic cases because the natural history is one of the growth and complications like rupture, spread, obstruction and rarely infection. The principles of treatment are to make the cyst cavity sterile, prevent spillage, remove all living elements (germinal epithelium and brood capsule), tackle open biliary communications and closed or pack the cavity. In the recent years, laparoscopic abdominal surgery has gained popularity because of its documented advantages i.e. reduced post-operative discomfort, accelerated recovery, decreased wound related complications<sup>[6]</sup>.

In our study 30 patients suffering from hydatid cyst liver were included, the exclusion criteria taken in our study was similar to the exclusion criteria in a study conducted by Palanivelu C et al.<sup>[1]</sup> who operated on 66 cases of hepatic hydatid cyst laparoscopically.

Most of our patients (50%) were in stage III. Sanglam A et al.<sup>[7]</sup> also graded hydatid cysts according to Gharbi and found 4 cysts in stage I and II and the remaining 2 were in stage III and IV. In our study, most common presentation was abdominal swelling whereas in some studies, majority of patients presented with abdominal pain<sup>[1,8]</sup>.

Right lobe of liver was involved in majority of the cases (76.66%) similar to other studies. The mean cyst size was  $9.61 \pm 2.47$  cm. (range from 5.5 to 14.5 cm) as against a mean cyst size of 11cm (range:4-22cm) observed in his study by Yavuz Ret al.<sup>[9]</sup> We used 10% povidone iodine as scolical agent as used by

Y Yagmur et al<sup>[10]</sup> whereas 20% hypertonic saline was in the study conducted by Yavuz R et al.<sup>[9]</sup>.



In our study the main surgical technique was puncturing of cyst with the Palanivelu Hydatid system cannula followed by that, instillation of 10% povidone iodine as scolicedal agent and then complete evacuation of cyst followed by unroofing the cyst. In a study conducted by Bickel A et al.<sup>[6]</sup>, the similar technique of puncture, parasite neutralization and complete evacuation was performed through an assembled transparent cannula. Al -Shareef Zet al.<sup>[11]</sup> used liposuction device for aspiration of cyst contents. Alper A et al.<sup>[12]</sup> used an aspirator and grinder apparatus system to sterilize cyst contents. Palanivelu C et al.<sup>[11]</sup> used a special trocar cannula system the Palanivelu Hydatid system (PHS) and performed simple evacuation of the hydatid cyst in 83.3% and in 13.7% because of large cyst size left lobectomy was done. Yavuz Ret al.<sup>[9]</sup> in his study aspirated the germinal membrane and daughter cysts with a 5mm aspirator and controlled the spillage with a second 5 mm aspirator which was inserted from another trocar. Use of Palanivelu Hydatid cannula was significant in preventing anaphylaxis.

We managed residual cyst cavity with drainage alone in 6 patients (20%), omentoplasty alone in 3 patients (10%) or omentoplasty and drainage in 21 patients (70%). Bickel A et al.<sup>[6]</sup> managed the cyst cavity by performing partial pericystectomy, omentoplasty and closed suction drainage in his patients. Ertem M et al.<sup>[13]</sup> also used omentoplasty in 15 out of 33 patients to obliterate the cystic cavity. C Palanivelu et al.<sup>[11]</sup> in his study on 75 patients used omentoplasty for dealing with remnant cavity in most of his patients.

In all the patients the drains were kept in the Morrison's pouch and cyst cavity mostly for a period of 5-10 days. In two patients with biliary fistula the drain was kept for 4 weeks which closed spontaneously after ERCP and sphincterotomy with stenting. Seven R et al.<sup>[5]</sup> kept the drain inside the cyst cavity for a period of 1-15 days depending upon the amount of drainage. The drain was removed after an average of 4.56 days in a similar study conducted by Patel N et al.<sup>[14]</sup>. In our series of 30 patients there was no conversion from laparoscopic to open similar to seen in other studies<sup>[15,16]</sup>. In other studies also, there was very small conversion rate. Rooh-ul muqimet al.<sup>[17]</sup> had a conversion rate of 6.97%. Samala DS et al.<sup>[8]</sup> also had a conversion rate of 3.12% due to excessive bowel adhesions to the cyst wall which were laparoscopically inaccessible.

The magnified laparoscopic view is an advantage to detect biliary openings, but in our study we did not encounter any such biliary communication during surgery. We had one case of diaphragmatic injury intra-operatively, but no other complication related to anesthesia, pneumoperitoneum or anaphylaxis. Post-operative complications were 10%, which include one port-site infection (3.33%) and two biliary fistulas (6.66%). Bickel A et al.<sup>[6]</sup> in his study on 31 patients had 5 peri-operative complications including one mortality due to candida sepsis. Palanivelu C et al.<sup>[11]</sup> reported infections in two patients (3%) and minor biliary leak in 9 (13.7%) that closed spontaneously by 5<sup>th</sup> post-operative day. Y Yagmuret al.<sup>[10]</sup> reported biliary leakage post-operatively in 7 patients among the 44 patients on which the procedure was performed, 5 of which stopped spontaneously by 7<sup>th</sup> postoperative day and in 2 patients ERCP was performed and leakage ceased after 48 hours. Majority of the patients (90%) had mild post-operative pain and discomfort.

The mean hospital stay was 8.06±3.70 days with a range of 5-20 days. Two patients had delayed discharge from the hospital because of biliary fistula. Yavuz R et al.<sup>[9]</sup> reported mean hospital stay of 6 days (range:3-9) and Samala DS et al.<sup>[8]</sup> observed a mean hospital stay of 5.22 (3-10 days).

In our study the patients were followed for the period up to 13.1±3.15months, during this period there was no recurrence in any of the patients with good subjective and objective cosmetic results as observed in a study conducted by Samala DS et al. [8] on 32 patients with a follow up of 3 years. Palanivelu Cet al. [1] in his study had a follow up period of 5.8years and reported no recurrence to date. Rooh-UI-Muqim et al. [17] in his study noted 2 recurrences (4.65%) at 6 months of follow up among the 43 patients who were operated.

We observed less post-operative morbidity in terms of less pain, rapid recovery, good cosmetic results and no recurrence in our follow up. We believe that intraoperative peritoneal hydatid dissemination can be prevented safely using Palanivelu hydatid system.

#### CONCLUSION:

We strongly recommend minimal access surgery as a superior and viable alternative in the treatment of hydatid cyst liver located in the laparoscopically accessible segments of liver although our experience remains limited to 30 cases. It has been found to be excellent procedure especially for supero-laterally located hepatic hydatid cyst, where open method would require extensive incision and mobilization of liver. The technique is easy to master and safe but is not recommended for cysts located deep in the parenchyma of the liver or posteriorly because of significant danger of hemorrhage and inaccessibility.

#### REFERENCES :

1. Palanivelu C, Senthikumar R, Jani K, Malladi V, Rajan PS, Parthasarathi R, Kavalakat. Palanivelu hydatid system for safe and efficacious laparoscopic management of hepatic hydatid disease. *JLS*. 2006 ;10(1): 56-62
2. Gomez R, Marcello M, Moreno E, Hernandez D, Calle A, Palamo J, Loinaz C, Trombatore G, Alvarado A, Hidalgo M. *Rev Esp Enferm Dig*. 1992 ;82(2):100-3
3. Verma G R and Bose S M. Laparoscopic treatment of hepatic hydatid cyst. *Surg Laparosc & Endosc*. 1998; 8 :280-82.
4. Katkhouda N, Fabiani P, Benizri E, Mouiel J. Laser resection of liver hydatid cyst under videolaparoscopy. *Br J Surg*. 1992;79:560-61
5. Seven R, Berber E, Mercan S, Eminoglu L, Budak D. Laparoscopic treatment of hepatic hydatid cysts. *Surgery*. 2000;128:36-40
6. Bickel A, Loberant N, Shtamler B. Laparoscopic treatment of hydatid cyst of the liver :initial experience with a small series of patients. *J Laparoendosc Surg*. 1994; 4(2): 127-33
7. Sanglam A. Laparoscopic management of liver hydatid cysts. *Surgical laparoscopy & endoscopy* 1996;6:16-21
8. Samala DS, Gedam MC, Gajbhiye R. Laparoscopic Management of Hydatid Cyst of Liver with Palanivelu Hydatid System over a Period of 3 Years: A Case Series of 32 Patients. *Indian J Surg*. 2015;77(3):918-22.
9. Yavuz R, Demircan F. Laparoscopic management of hydatid disease of liver: experience of single center: experience of single center, *World J Laparosc Surg*, 2013; 6 :98-101
10. Y. Yağmur, S. Akbulut, S. Güümü, M. Babür, M. A. Can. Laparoscopic management of hydatid cyst of the liver. *SAfr J Surg*. 2016 Sep; 54(3): 14–17.
11. Al-Shareef Z, Hamour OA, Al-Shlash S, Ahmed I, Mohamed AA. Laparoscopic treatment of hepatic hydatid cysts with a liposuction device. *JLS*. 2002; 6:327–330.
12. Alper A, Aliemere, Acarli K et al. Laparoscopic treatment of hepatic hydatid disease. *Journal of laparoendoscopic surgery* 1996;6:29-33.

13. Ertem M, Karahasanoglu T, Yavuz N, Erguney S. Laparoscopically treated liver hydatid cyst. *Arch Surg.* 2002; 137(10):1170–73.
14. Patel NJ, Khandra HP, Chhabra SR, Singh CBP. Evaluation and comparison of the outcomes of open and laparoscopic surgery of liver hydatid cyst. *IAIM*, 2016; 3(4): 118-124.
15. Altinli E, Saribeyoglu K, Pekmezci S, Uras C, Taşçi H, Akçal T, et al. An effective omentoplasty technique in laparoscopic surgery for hydatid disease of the liver. *JLS.* 2002;6:323–326.
16. Chowbey PK, Shah S, Khullar R, Sharma A, Soni V, Baijal M, et al. Minimal access surgery for hydatid cyst disease: Laparoscopic, thoracoscopic, and retroperitoneoscopic approach. *J Laparoendosc Adv Surg Tech.* 2003;13(3):159–165
17. Rooh ul-Muqim, Kamran K, Khalil J, et al. Laparoscopic treatment of hepatic hydatid cyst. *J Coll Physicians Surg Pak.* 2011;21:468–471.